

NONSURGICAL TIGHTENING OF SKIN LAXITY: A NEW RADIOFREQUENCY APPROACH

Antonio Rusciani MD,^a Giuseppe Curinga MD,^a Giulio Menichini MD,^b
Carmine Alfano MD,^b Luigi Rusciani MD^c

a. Division of Dermatology, Plastic and Reconstructive Surgery, University of Rome "La Sapienza," Italy

b. Division of Plastic and Reconstructive Surgery, University of Perugia, Italy

c. Dermatologic Institute of Rome, U.C.S.C., Italy

Abstract

Background: Improvement in skin laxity can be difficult to achieve without invasive surgical procedures. Monopolar radiofrequency (RF) treatment is used by physicians to heat skin and promote tissue tightening and contouring. RF technology produces an electric current that generates heat through resistance in the dermis and subcutaneous tissue. The thermal effect depends on the conductivity features of the treated tissue. When heated, collagen fibrils will denature and contract, which is believed to lead to the observed tissue tightening.

Methods: Ninety-three consecutive patients with mild to moderate laxity were included in the study. The Surgitron Dual Frequency™ RF (Radiowave technology, Ellman International) was used to treat skin laxity. The application of RF energy took place in an ambulatory setting with no need for skin sterilization or anesthesia.

Results: Patients immediately noticed a microlifting retraction in the treated tissues according to the vectors mapped in the area. There were no significant complications and the majority of patients were satisfied with the procedure and able to return to their daily routine after leaving the office, thereby substantiating the popularity of noninvasive rejuvenating procedures.

Introduction

Skin laxity is a common cosmetic complaint of aging patients. Evidence of the desire to rejuvenate has been seen as early as the ancient Egyptian Ebers papyrus (1560 BC).¹ Improvement in skin laxity can be difficult to achieve without invasive surgical lifting procedures. In the early 20th century, there was a renewed interest in skin resurfacing. Early resurfacing techniques involved direct application of minerals, plant extracts, sulfur, mustard, or limestone. The rapid evolution of laser resurfacing procedures occurred because technological advances and consumer-driven marketing fueled public demand for less invasive procedures. Many patients prefer the subtle improvements in skin texture and wrinkling from nonablative laser treatment to the more obvious improvements from ablative laser resurfacing because of the lower risk of complications, shorter recovery time, and less disruption of regular activities.

The radiofrequency (RF) system is based on an entirely different treatment principle than the photothermal reaction created by most dermatologic lasers. Unlike a laser, which uses light energy to generate heat in targeted chromophores based on the theory of selective photothermolysis,² RF technology produces an electric current that generates heat through resistance in the dermis and subcutaneous tissue. The Surgitron Dual Frequency™ RF (Radiowave technology, Ellman International) uses a proprietary capacitive coupling method to transfer higher energy fluences through the skin to a greater volume of dermal tissue than nonablative lasers while protecting the epidermis.³

The depth and degree of thermal injury depends on the geometry and size of the treatment tip and the conductive properties of the tissue being treated, respectively. Tissues with higher impedance (ie, subcutaneous fat) generate greater heat, thus resulting in a deep tissue thermal effect.^{4,5}

Materials and Methods

The Surgitron Dual Frequency RF heats tissue using a proprietary method of coupling monopolar RF to skin by a thin capacitive membrane that distributes RF energy over a volume of tissue beneath the membrane surface. The components of the device include: 1) an RF generator producing a 4-MHz alternating-current RF signal, the energy level of which is set by the clinician; and 2) a handpiece for direct-

Figure 1. Surgitron Dual Frequency™ RF and spherical handpieces.



ing the RF energy to the skin (Figure 1). The neutral plate of the apparatus is placed approximately at 15 to 20 cm from the patient. Spherical handpieces (0.5 cm in diameter) are used. The application of RF energy has been carried out in ambulatory settings with no need for skin sterilization.

Ninety-three patients in 2 separate group studies (83 female, 10 male, mean age of 53.3 years; skin phototypes I to IV) with mild to moderate skin laxity were included in the study after informed consent was obtained. Photographic documentation using identical camera settings, lighting, and patient positioning was obtained at baseline and immediately after treatment at 1 week, and at 1, 3, and 6 months after treatment. Patients with a history of ablative laser skin resurfacing, dermabrasion, phenol peel, nonablative laser procedure, or temporary filler (eg, collagen, fat, hyaluronic acid) injections within 2 years of study initiation were excluded.

Figure 2. Grading scale: 0=<25%, 1=25% to 50%, 2=51% to 75%, 3=>75%.

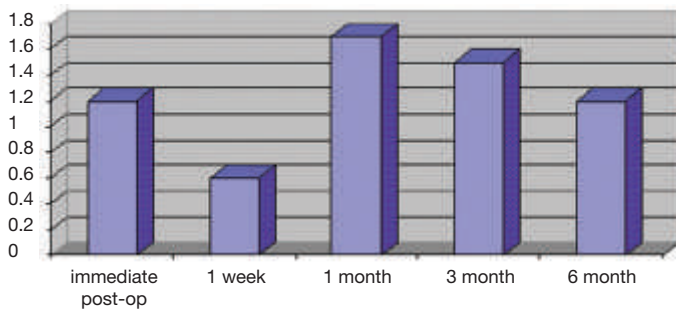
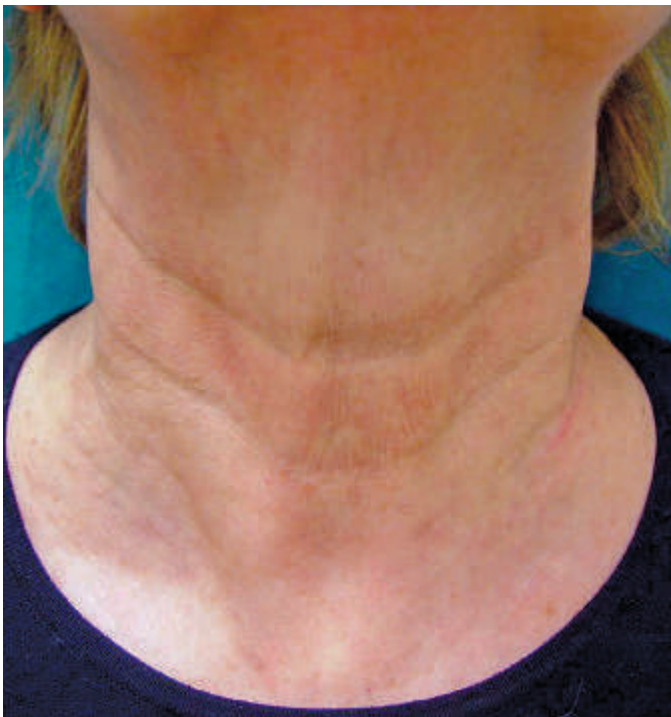

Figure 3a. Preoperative laxity of neck.

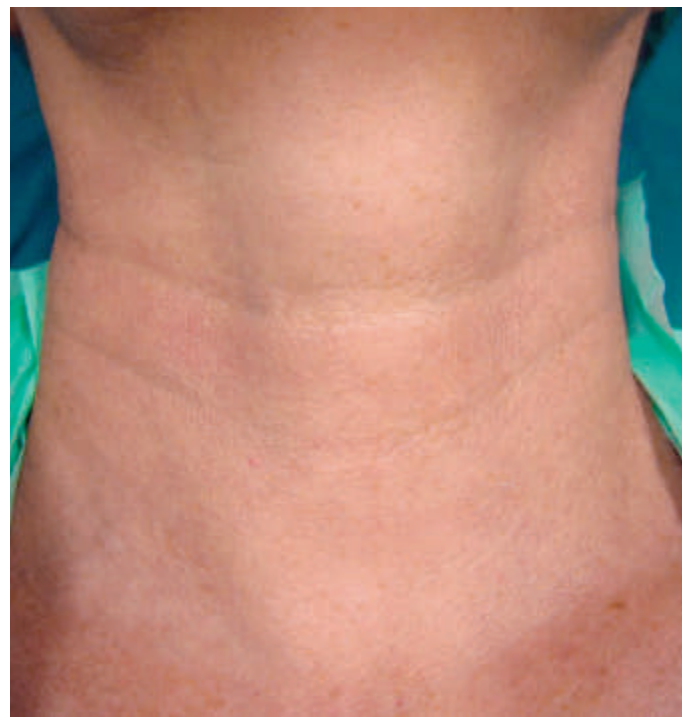

The Surgitron 4.0 Dual RF has various operative modes. For ideal treatment the manufacturer recommends a setting of 4.0 Mhz. The patients were informed that for maximum benefit, the sensation should feel as if the skin is heating just to the brink of pain, but then subsiding. The settings were adjusted based on each individual patient's comfort level.

Settings may vary for each anatomic region (forehead cut/coag blue 2.5–3 white 3–3.5, cheek and other surface cut/coag blue 3–3.5 white 3.5–4). The handpiece traces out spiral vectors against gravity in a diameter of approximately 1 cm. Based on the patient's characteristics (subcutaneous fat distribution), a greater pressure of the handpiece was applied to cheeks and other body areas, but practically absent on the forehead. The handpiece action effectiveness is proportional to the pressure applied. The treatment time varies according to the area (15–20 min average). The burning sensation may vary per area as well (a more intense pain is perceived on the forehead). For patients with a high cutaneous dryness, in order to reduce the skin-handpiece friction, the use of a restoring cream is vital.

In order to diminish the side effects (ie, small abrasions healing in 3–4 days) it is important that the patient remain still during treatment. After treatment, an antidystrophic and restoring cream is applied. The degree of clinical improvement was independently determined by 3 blinded assessors who were randomly assigned comparative before and after treatment photographs using a quartile grading scale (0=less than 25%, 1=25% to 50%, 2=51% to 75%, 3=more than 75% improvement). At the end of the study, the subjects documented their degree of satisfaction on a scale of 1 (lowest)

Figure 3b. Postoperative view of neck.



to 10 (highest) for the treated area (Figure 2). Side effects of the RF treatment were documented at each follow-up evaluation. Patients were typically able to return to work and social activities immediately after treatment.

Results

The treatment was generally well-tolerated with patients describing the procedure as moderately uncomfortable. Patients immediately noticed a microlifting retraction in the treated tissues according to the vectors mapped. The treated areas appeared to be erythematous and hot. The erythema persisted for 2 to 6 hours. During the postsurgical period, a restoring cream was applied for 3 to 4 days. No sunscreen

with protective properties is required since the skin's integrity is ensured and the melanocyte undergoes a very slight thermal stress.

The results that can be immediately noticed in the postoperative stage persist for about 36 to 72 hours. After this interval a tissue relaxation takes place. Then after 7 to 10 days the contraction of elastin and the newly produced collagen resume as usual. Intervals between 2 applications should range from 1 to 3 months.⁶

All of the patients in the study expressed satisfaction with the skin contraction, elasticity, and hydration in the immediate postoperative period. Approximately 20% of the patients

Figure 4a. Preoperative skin laxity of neck.

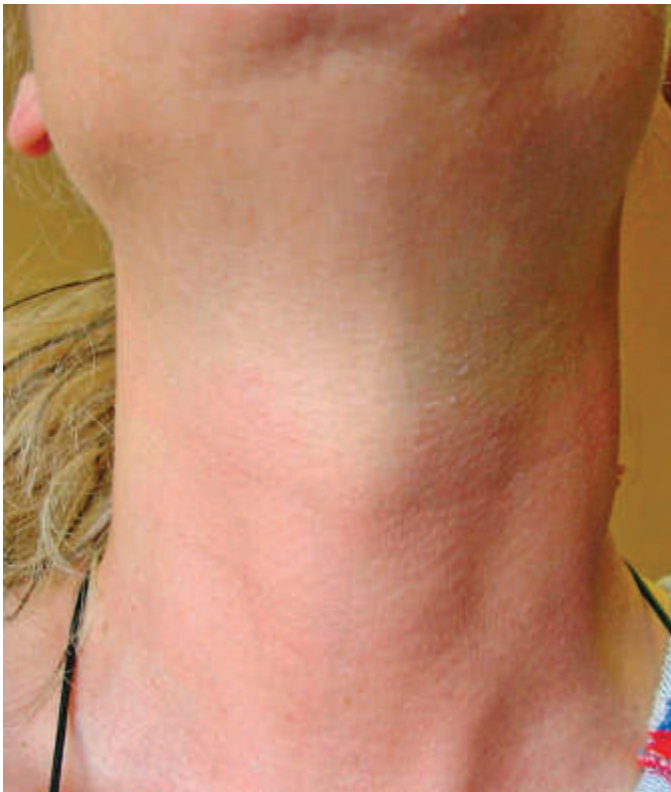

Figure 5a. Preoperative forehead wrinkles.

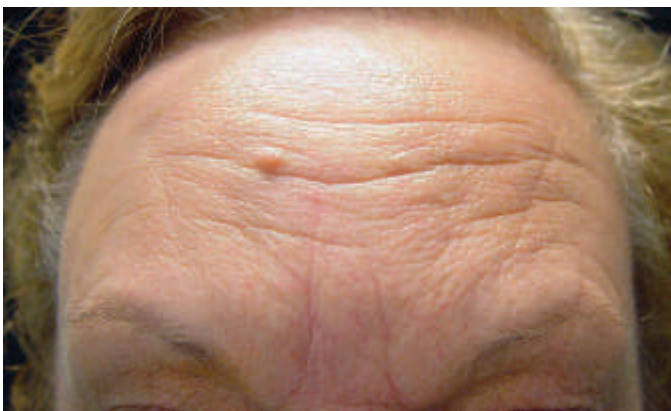

Figure 4b. Postoperative view of neck.

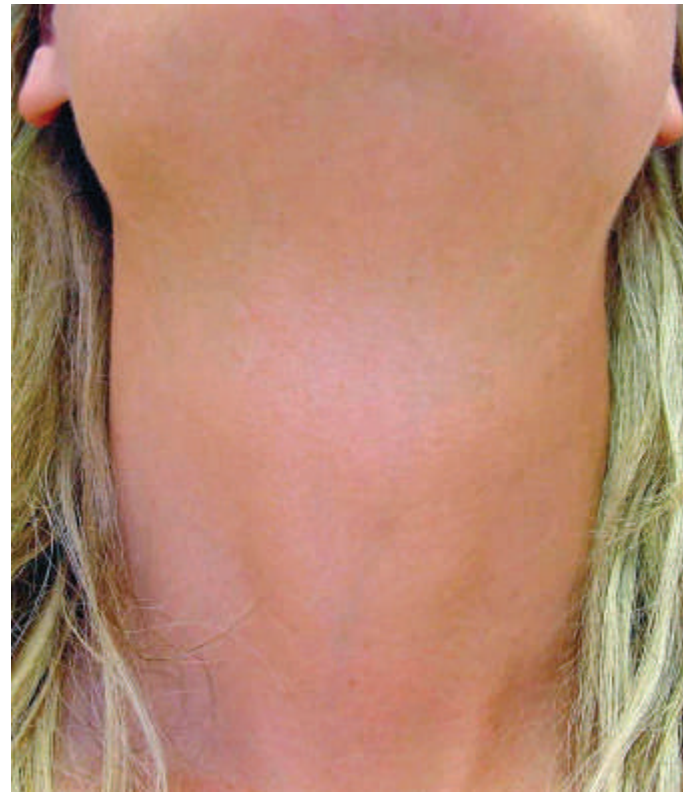
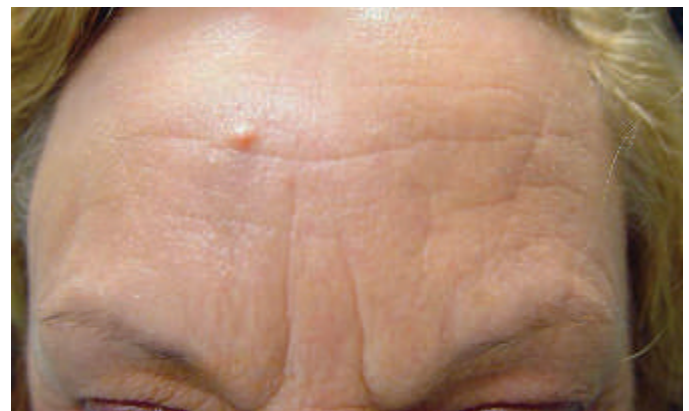
Figure 5b. Postoperative view of forehead.



stated dissatisfaction when the cutaneous contraction was absent, but 20 to 30 days later they said they were satisfied as the contraction of the treated tissues was becoming stable. There were no serious adverse affects. In 2 patients, there were small abrasions healing in 3 days. Mild asymmetries were reported in 3 patients. Most of the patients in our study felt that they had benefited from the procedure and requested treatment to an additional area (Figures 3-8).

Discussion

RF energy has been used to treat cardiac arrhythmias,⁷ benign prostatic hypertrophy,⁸ sleep apnea,⁹ and for endovenous closure of the saphenous vein.¹⁰ It is also approved for dermatologic and general surgical procedures for electrocoagulation and haemostasis. The high frequency (4.0 Mhz) of the electric current converts the latter into a simple radio wave. This wave emitted by the active electrode naturally goes toward the passive one. Between the 2 electrodes, the organic tissue hinders the radio wave flow. At a molecular level, this resistance turns into an intracellular oscillation leading to a break in links among the water molecules contained in the organic tissue and to the related linking energy release. The thermal effect depends on the characteristics of the treated

tissue conductivity. Therefore, tissues with a higher impedance (ie, the adipose ones) produce a greater heat and consequently a greater thermal effect. In this way, the energy produced by RF can develop a heat that is determined and controlled according to the superficial and deep dermis, as well as to the adipose tissue up to the muscle border.

The thermal effect is determined by the formula: energy (J) = $I^2 \times R \times T$ (I=current, R=impedance of the tissue, and T=time of application).

Studies indicate that tissue tightening occurs through a mechanism of immediate collagen contraction, supplemented by new collagen synthesis during a longer-term wound healing process. Ultrastructural analysis of human tissues immediately after treatment revealed isolated, scattered areas of denatured collagen fibrils with increased diameter and loss of distinct borders.¹¹ When heated, collagen fibrils will denature and contract, which is believed to lead to the observed tissue tightening. Monopolar RF treatment has also been demonstrated to induce a wound-healing response in an animal model resulting in fibroplasia and increased collagen.¹² Increased collagen gene expression has also been demonstrated in monopolar RF-treated human skin.⁴

Figure 6a. Preoperative skin laxity of arm.

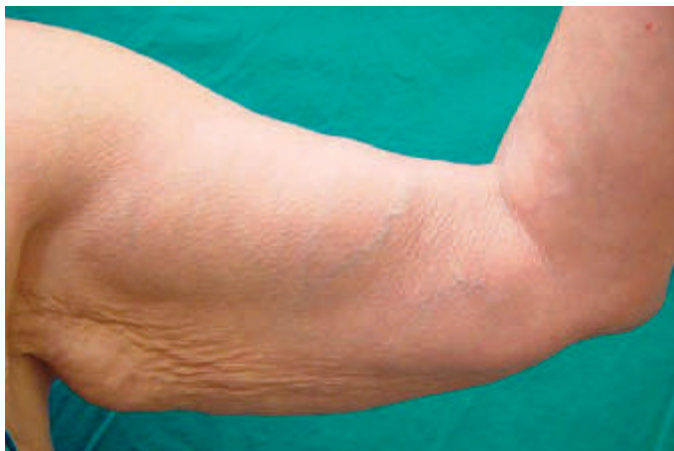

Figure 6b. Postoperative view after 6 months.

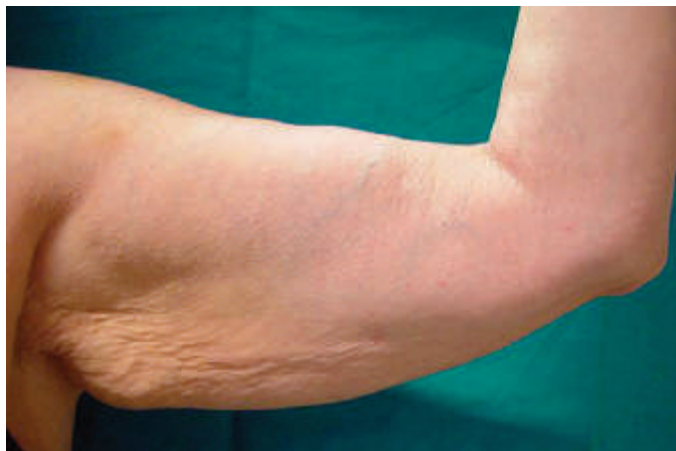

Figure 7a. Pre- and postoperative view of face skin laxity.

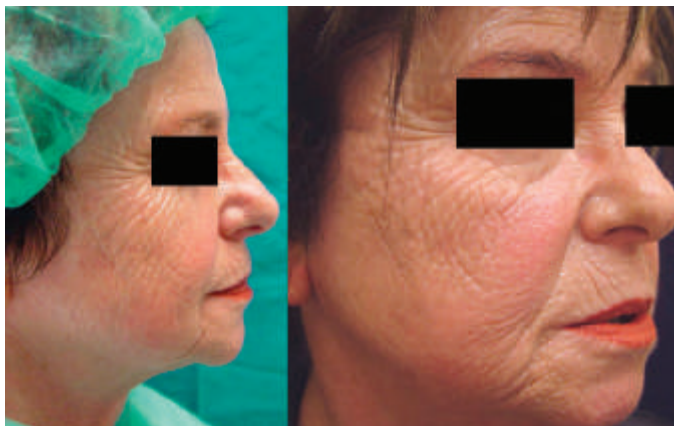
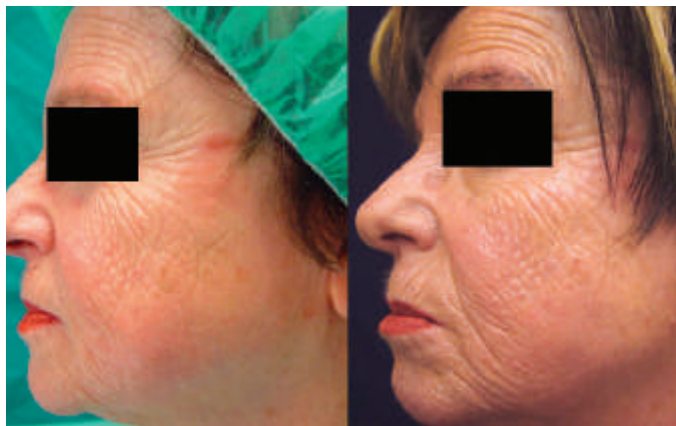

Figure 7b. Pre- and postoperative view of face skin laxity.



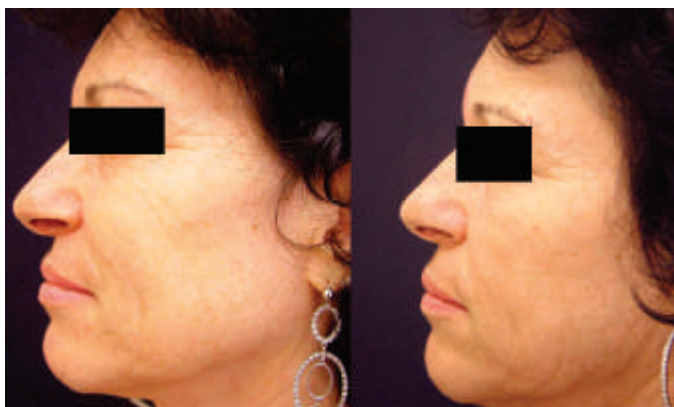The contraction determines a reorganization of the cutaneous tension lines in a physiological way with a reduction in cutaneous laxity caused by a tightening effect similar to microlifting. In contrast to the literature on Thermage's RF device, we report additional information on the efficacy and adaptability of the Surgitron Dual Frequency RF. The innovations in our study show it is possible to treat new areas of the body with RF energy without any anesthesia and in ambulatory settings. Furthermore, the equipment does not require any external cooling of the cutaneous surface.

The Dual Surgitron handpiece is extremely versatile, allowing application and adjustment of the RF energy according to antigravitational factors. The Thermage equipment has rectangular or square electrodes with larger dimensions that can cause a contraction of the treated area's perimeter, making the contraction itself in the geometric shape. The typical pain reported by patients is actually due to the greater dimensions. The larger handpiece dimensions of the Thermage device can cause side effects such as burns and other untoward results.¹³ The larger the treated area the deeper the effects. The smaller Dual Surgitron with a specially designed RF electrode tip (0.5 mm) combined with rapid hand movement greatly reduces the deep side effects.

It is specifically designed with a novel shape and size—an advanced alloy matched to the radio wave circuit—and has a very high conductivity acting as a heat sink to protect against increases in heat. This will hopefully discourage doctors from using classical ball electrodes and standard electrosurgery machines to do the nonablative noninvasive skin tightening. The parameters to be taken into account for an ideal treatment are still disputable, just as the ideal level of energy needed to achieve the best result is still unknown. In our study, no anesthetic was used. The energy and the treatment mode have been carefully adjusted so as to produce a level of heat not causing any epidermic damage or excessive pain in the area treated. Moreover, applying the tip of a 0.5 mm electrode with circular movements seems to help evenly disperse the RF electricity.

The complication rate was very low for our study. We did not have any of the blistering, long-lasting erythema, or indurations that had been previously reported. Since anesthetics

Figure 8. Pre- and postoperative view of face skin laxity.



were not used, patients could perceive any exceeding electrothermal effect, thus preventing any complications.

It is interesting to note that patients not showing a clear improvement did achieve a better skin quality and a reduction in cutaneous laxity, as can be seen by the before and after pictures, even though the improvement was not very evident and therefore not perceivable by the patients themselves. For this reason, it is important to consider the patient's expectations and to explain chances for real improvement as well as the perception appraisal. Of course, an informed consent should also be obtained and patients should be shown examples of before and after pictures from the literature shown.

Since RF treatment is not invasive, the results clearly cannot be compared with those of surgical procedures. In successful cases, the treatment effectiveness can be immediately perceived and continue to improve during the following 6 to 8 months. A 2-year follow-up has shown that the results can last at least 8 to 14 months. The treatment can be repeated after a minimum of 6 months.

RF treatments can safely be used with intense pulsed light, nonablative lasers, biorevitalizers, botulin complexes, and fillers, although these additional treatments were not used by patients participating in the study. The majority of patients were satisfied with the procedure and liked the ability to return to their daily routine after leaving the office.

Conclusions

RF skin tightening is a new and very promising tool for the nonsurgical tightening of loose or sagging skin. In its current configuration, most patients will see at least a mild improvement while experiencing minimal downtime and minimal risk. We determined that for in-office rejuvenation of the skin the Dual Surgitron RF device provides a measurable improvement in the majority of patients treated. The Ellman Dual Surgitron and specifically designed RF tip is an effective, noninvasive, economical, and safe tool. This technology offers a very attractive alternative to invasive procedures. Costs connected to this new method are rather low. Even the less expert professionals can be easily trained on this technology due to the low risks involved in its use.

References

1. Ebbell B, translator. *The Papyrus Ebers: The Greatest Egyptian Medical Document*. Copenhagen: Levin & Munksgaard; 1937.
2. Anderson RR, Parrish JA. Selective photothermolysis. Precise microsurgery by selective absorption of pulsed radiation. *Science*. 1983;220:524-527.
3. Hardaway CA, Ross EV. Nonablative laser skin remodeling. *Dermatol Clin*. 2002;20:97-111
4. Tunnel JW, Pham L, Stern RA, et al. Mathematical model of nonablative RF heating of skin. *Lasers Surg Med*. 2002;14(suppl):318.
5. Hsu TS, Kaminer MS. The use of nonablative radiofrequency technology to tighten the lower face and neck. *Semin Cutan Med Surg*. 2003;22:115-123.
6. Narins DJ, Narins RS. Non-surgical radiofrequency facelift. *J Drugs Dermatol*. 2003;2:495-500.

7. Jackman WM, Wang XZ, Friday KJ, et al. Catheter ablation of accessory atrioventricular pathways (Wolff-Parkinson-White syndrome) by radiofrequency current. *N Engl J Med*. 1991;324: 1065-1011.
8. Issa M, Oesterling J. Transurethral needle ablation (TUNA): an overview of radiofrequency thermal therapy for the treatment of benign prostatic hyperplasia. *Current Opinion in Urology*. 1996;6: 20-27.
9. Powell NB, Riley RW, Troell RJ, et al. Radiofrequency volumetric reduction of the tongue. A porcine pilot study for the treatment of obstructive sleep apnea syndrome. *Chest*. 1997;111:1348-1355.
10. Weiss RA, Weiss MA. Controlled radiofrequency endovenous occlusion using a unique radiofrequency catheter under duplex guidance to eliminate saphenous varicose vein reflux: a two year follow up. *Derm Surg*. 2002;28:38-42.
11. Zelickson BD, Kist D, Bernstein E, Brown DB, Ksenzenko S, Burns J, Kilmer S, Mehregan D, Pope K. Histological and ultrastructural evaluation of the effects of a radiofrequencybased nonablative dermal remodeling device: A pilot study. *Arch Dermatol*. 2004;140: 204-209.
12. England LJ, Tan MH, Shumaker PR, Egbert BM, Pittelko K, Orentreich D, Pope K. Effects of monopolar radiofrequency treatment over soft-tissue fillers in an animal model: Part 1. *Lasers Surg Med*. 2005;37:356-65.
13. Ruiz-Esparza J, Gomez JB. The medical face lift: A noninvasive, nonsurgical approach to tissue tightening in facial skin using non-ablative radiofrequency. *Dermatol. Surg*. 2003;29:325.

ADDRESS FOR CORRESPONDENCE

Antonio Rusciani MD
Piazzale delle Belle Arti, 2
00196 – Roma, Italy
Phone: 0039-06.36005484
Fax: 0039-06.36088986
e-mail: skinlaser@skinlaser.it